

VERTICAL VERSUS TRANSVERSE INCISION FOR THE RELEASE OF THE FIRST DORSAL COMPARTMENT OF THE WRIST FOR DE QUERVAIN'S TENOSYNOVITIS

Israr Ahmad¹, Sabir Khan Khattak², Noor Rehman³, Wasim Anwar⁴, Aamir Kamran⁵, Azhar Hayat Khan⁶,
Abdullah Durrani⁷

Correspondence

³Noor Rehman, Assistant Professor,
Department of Orthopaedics, Khyber
Girls Medical College/Hayatabad
Medical Complex, Peshawar
☎: +92-333-9702717

✉: noor_elum@yahoo.com

¹Associate Professor, Department of
Orthopaedics, Khyber Girls Medical
College/Hayatabad Medical Complex,
Peshawar

²Resident Orthopedic Surgeon
Department of Orthopaedics, Khyber
Girls Medical College/Hayatabad
Medical Complex, Peshawar

⁴Associate Professor, Department of
Orthopaedics, Khyber Girls Medical
College/Hayatabad Medical Complex,
Peshawar

⁵Registrar, Department of
Orthopaedics, Khyber Girls Medical
College/Hayatabad Medical Complex,
Peshawar

⁶Resident, Orthopedic Surgeon,
Hayatabad Medical Complex, Peshawar

⁷Department of Trauma &
Orthopaedics, University Hospital
Dorset, UK

How to cite this article

Ahmad I, Khattak SK, Rehman N,
Anwar W, Kamran A, Khan AH, et al.
Vertical Versus Transverse Incision
for the Release of the First Dorsal
Compartment of the Wrist for De
Quervain's Tenosynovitis. J Gandhara
Med Dent Sci. 2023;10(3): 31-34
<https://doi.org/10.37762/jgmgs.10-3.456>

INTRODUCTION

De Quervain disease was described in 1895 by the Swiss physician Fritz de Quervain. This condition involves tendon disorders that affect the first dorsal compartment of the wrist.^{1,2} The first dorsal compartment of the wrist contains the abductor pollicis longus (APL) and extensor pollicis brevis (EPB) tendons. The tendon sheath is swollen and inflamed in a fibrous bone tunnel located along the distal radius of the wrist. The symptom is wrist pain that is exacerbated by thumb movement. The radial styloid process is tender, and this area may be swelling. There is a classical presentation of pain that is made worse by thumb movement. Ulnar deviation with flexed thumb in the palm is the basis of the Finkelstein test.^{2,3,4,5} The pathology of this disease is unknown, but the

contributory factors are believed to be myxoid degeneration with the deposition of fibrous tissue and increased inflammation of the synovial membrane. The tendon sheath is thickened, accompanied by painful pinching. Typical patients are mothers with young children or other manual workers.^{4,6,7,8} The x-rays are taken to rule out other medical conditions such as arthritis or non-scaphoid union and rarely infection or tumours.⁹ The prevalence of de Quervain tendonitis ranges from 0.6% in men to 1.5% in women, with more cases occurring in the 40s and 50s of life. More recently, the use of smartphones and other handheld devices and repeated use of the thumb for texting has been reported to be a major cause.^{10,11,12} The disease is also commonly associated with other work-related upper extremity musculoskeletal disorders, such as medial and lateral epicondylitis.⁹ Bilateral involvement

ABSTRACT

OBJECTIVES

The study aimed to compare the clinical outcome of transverse versus longitudinal incision for surgical release of the first dorsal compartment of the wrist to treat de Quervain's disease.

METHODOLOGY

In this quasi-experimental study, all the patients with resistant de Quervain's tenosynovitis who had the surgical release of the first dorsal compartment between January 2008 and December 2020 were included. The surgeries were performed under local anaesthesia. The first dorsal compartment of the wrist was approached through either a longitudinal or transverse incision, and the tendons of the abductor pollicis longus and extensor pollicis brevis were released. Patients were followed for a minimum of three months, and the primary outcome measure was the Visual analogue score (VAS) for relief of pain and secondary outcome measures were any immediate or delayed complications.

RESULTS

98 patients were included in the study with a female-to-male ratio of 7:1. The cohort's mean age was 44 years (Range 25-75). Most patients were housewives exposed to manual work with the involvement of the dominant hand. There were no major complications besides wound issues and transient paresthesia in few patients. The longitudinal incision was associated with less transient nerve palsies, less duration of surgery and easier identification of structure and anomalies. The only advantage of transverse incision was less scar formation. The clinical outcome was similar in both groups: 94% of patients had complete pain relief (VAS 0).

CONCLUSION

There was no difference in the outcome of de Quervain tenosynovitis when released with a transverse or longitudinal incision. The longitudinal incision had fewer complications as compared to the transverse incision.

KEYWORDS: De Quervain's Disease, Tenosynovitis, Extensor Pollicis Brevis, Abductor Pollicis Longus, Surgical Release. Transverse Incision

is commonly reported in mothers of young infants or babysitters.⁸ Many cases of de Quervain's disease get better with rest and changes in activity.⁹ Those who make no response to rest are treated with splinting of the wrist, analgesics and sometimes with local steroid injections.^{1,4,7,13} Corticosteroid injections are very effective for various researchers. The injection is made into the tendon sheath about 1 cm proximal to the radial styloid process, where the tendon can be palpated. The injection should not be into the substance of the tendon but rather into the sheath. Response to a single steroid injection is about 40-50%.^{4,7,13} The injection can be repeated after 4-6 weeks, and the response improves from 50- 80%. Local steroid injections have fewer side effects, but local fat necrosis and depigmentation can sometimes occur. Tendon tears are very infrequently seen but can occur if the steroid is directly infiltrated into the substance of the tendon.^{3,13} Surgery is indicated if these conservative measures fail.^{14,15,16,17} The procedure is a day-case surgery done under local anaesthesia. A tourniquet is used to get a clear field and should be quickly done to avoid ischemic pain. This procedure is performed through a transverse or longitudinal skin incision approximately 3-4 cm long over the first dorsal compartment. Care must be taken not to damage the branches of the superficial radial nerve. Ligaments on the first dorsal compartment are exposed. Then make a vertical incision at the end of the sheath. If there are subcompartments, they are identified and released. The skin is closed when all compartments are freed and a bulky bandage is applied. Early finger exercises are recommended for the patient, who is encouraged to use their hands.^{14,16,18,19,8,20} There is some debate about using transverse or longitudinal planes. Most surgeons prefer a longitudinal incision because it is simpler and less likely to damage superficial branches of the radial nerve. It is faster to operate and easier to identify structures. However, this condition is more common in women, and because the incision is made perpendicular to the skin fold, there is concern that it may leave an unsightly scar behind the wrist. Sutures are removed on day ten, and the patient can resume normal activities. Patients may complain of swelling and pain for several months, but this disappears permanently.^{15,16,21} There are usually few major postoperative complications associated with this surgery. Surgical site infection, wound deterioration, or necrosis is very rare. The superficial branches of the radial nerve can be damaged by direct, sharp instruments or traction pressure associated with scarring. This is more common with transverse incisions. Signs of this nerve damage are pain and paresthesia in this area.^{1,8,22} Sometimes there is bowstringing of tendons. This is usually caused by excessive exposure of the tendon sheath during surgery

and is common with longitudinal incisions.^{22,23} This study aimed to compare the results of transverse and longitudinal incisions for surgically releasing the first dorsal compartment of the wrist to treat de Quervain's disease.

METHODOLOGY

Data for this quasi-experimental study was retrospectively collected in a Microsoft Excel spreadsheet (2013 Microsoft Ltd.) from two hospitals in Peshawar. Simple numerical calculations were performed for most results, and P-value was calculated to ascertain statistically significant differences in VAS scores before and after surgery. All consecutive patients who underwent surgical release of the first dorsal compartment from January 2008 to December 2020 were included in the study. All adult patients who gave informed consent failed non-surgical treatments, and had a minimum of 3 months follow-up were included in the study. All patients undergoing surgery at our hospital receive institutionally approved informed consent. This contains confidential use of patient data for educational and research purposes and serves as blanket approval from the local Ethics Committee. Ninety-eight (n=98) patients were considered eligible for inclusion in this study. Their pre and postoperative VAS scores at three months of follow-up were recorded, which was the primary endpoint, and all surgical complications (measures of secondary outcomes) were also recorded. We compared outcomes and complication rates in the transverse and longitudinal incision groups to see if there was a significant difference between the two groups, although the transverse incision group had a smaller number of 74 to 24. The surgical procedure was performed in a sterile operating room. The forearm was positioned supine on an arm table. With a tourniquet applied. A qualified surgeon operated all the patients as a day case procedure under local anaesthesia (2% Xylocaine). Longitudinal or transverse incisions were performed on the patients on the first dorsal compartment of the wrist. Abductor pollicis longus (APL) and extensor pollicis brevis (EPB) tendons were identified when looking for anatomical variations, like sub-compartment or duplications, and the release was made accordingly. The skin was closed with interrupted non-absorbable stitches, and a non-adhesive and compression bandage was applied. The patients were prescribed antibiotics and pain relievers for three days. Patients were reviewed at two weeks, six weeks, and three months after surgery, and the VAS score at the last follow-up was recorded, and the patient was discharged if there were no complications and all symptoms had disappeared.

RESULTS

Table 1: Distribution of Patients According to Gender (n=60)

Patients Operated (n)	98
Females	86(87.7%)
Males	12(12.2%)
Mean age	43 Years (Range: 25-75)
Bilateral	08(8.1%)
Right Side	90(91.8%)

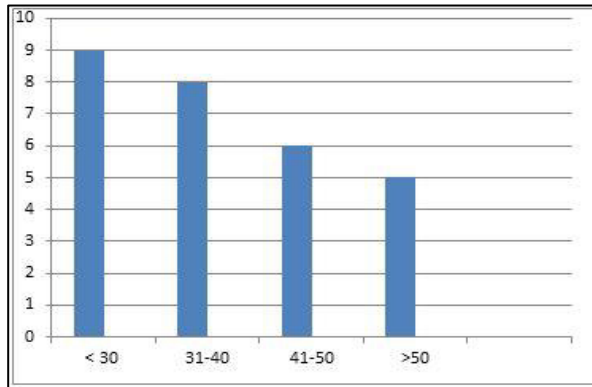


Figure 1: Age Distribution of Operated Patients (n=98)

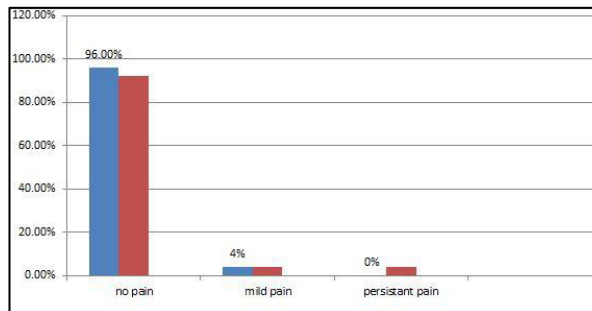


Figure 2: Clinical Outcome of Surgery (n=98)

Table 2: Comparison of Longitudinal vs Transverse Incision Groups

	Transverse Incision (n=24)	Vertical Incision (n=74)	P-Value*
The average size of the incision	4 cm	3.5 cm	>0.05
The average duration of surgery	16 minutes	12 minutes	>0.05
Post op paresthesia	06(25%)	02(2.7%)	>0.05
Hypertrophic scar	0(0%)	03(4%)	>0.05
Tendon bowstringing	0	0	>0.05
Wound infection	02(8.3%)	01(1.4%)	>0.05

*Chi-square test used

DISCUSSION

De Quervain's tenosynovitis can be treated in most cases with conservative measures. However, some cases may not respond to only conservative treatment; in such cases, surgical release of the first compartment of the wrist is the treatment of choice. The outcome of

surgery is predictable, and most patients are completely cured of the disease. This a common orthopaedic procedure, and the complication rates are very low when performed properly.^{13,14,16,21} Our study's female-to-male ratio was 7:1, slightly lower than previous studies.^{15,18} In a study by Zarin M and the present author, the ratio was 9:1 in 2003.¹⁴ Although this trend has been reversed in recent years due to smartphone use, and an increasing number of men are affected.^{11,12} The mean age of our patient was 43 years, slightly higher than our previous study. But compared to most other studies.^{1,4,14} In this study, we compared transverse and longitudinal incisions. Although the transverse group had fewer cases, we still found some differences. The disease is more common in females, and most surgeons prefer transverse incisions to avoid crossing skin creases, thus avoiding unsightly scar formation. The complication rate is far less with vertical incisions.^{16,20} The transverse incision is also associated with a longer duration of surgery and some technical difficulty in dissection. Secondary compartments or tendon sheaths were present in 14 (15%) cases. In a previous study by Zarin M et al, the proportion of sub compartment was lower, but the data size was too small, so we could conclude that this might be more representative of the community.¹⁴ During the follow-up period, although short, there were no major complications. Many patients experienced transient paresthesia in the transverse incision group; most subsided over time. Three patients had superficial wound problems resolved with wound care and antibiotics. One patient in the longitudinal incision group needed scar excision due to bad scar formation following wound infection. There was no pain with a negative Fenkestein test in 94% of patients in both groups after three months of follow-up. These results are comparable with most published literature.^{14,16,23}

LIMITATIONS

Our study has some limitations as the number of cases in each group is not equal to 24 vs 74. Conducting properly randomized trials to compare two incision types is recommended, although we did not find any statistically significant difference.

CONCLUSIONS

Our study concludes that both Vertical/longitudinal incisions are good as far as the outcome of surgery is concerned in treating de Quervain tenosynovitis. The vertical incision group had slightly fewer complications than transverse incisions in surgically treating resistant or chronic De Quervain tenosynovitis.

CONFLICT OF INTEREST: None

FUNDING SOURCES: None

REFERENCES

1. Harvey FJ, Harvey PM, Horsley MW. De Quervain's disease: surgical or non-surgical treatment. *J Hand Surg Am.* 1990;15(1):83-87
2. Jaworski CA, Krause M, Brown J. Rehabilitation of the wrist and hand following sports injury. *Clinic Sports Med.* 2010 Jan; 29(1):61-80
3. Rettig AC. Wrist and hand overuse syndromes. *Clin Sports Med.* 2001 Jul; 20(3):591-611.
4. Ilyas AM. Non-surgical treatment for de Quervain's tenosynovitis. *J Hand Surg Am.* 2009 May-Jun; 34(5):928-9
5. Alexander RD, Catalano LW, Barron OA, Glickel SZ. The extensor pollicis brevis entrapment test in the treatment of de Quervain's disease. *J Hand Surg Am.* 2002;27(5):813-816.
6. Clarke MT, Lyall HA, Grant JW, Matthewson MH. The histopathology of de Quervain's disease. *J Hand Surg Br.* 1998;23(6):732-734
7. Moore JS. De Quervain's tenosynovitis: stenosing tenosynovitis of the first dorsal compartment. *J Occup Environ Med.* 1997;39(10):990-1002.
8. Capasso G, Testa V, Maffulli N, Turco G, Piluso G. Surgical release of de Quervain's stenosing tenosynovitis postpartum: can it wait? *Int Orthop.* 2002; 26(1):23-5.
9. Palmer K, Walker-Bone K, Linaker C, et al. The Southampton examination schedule for the diagnosis of musculoskeletal disorders of the upper limb. *Ann Rheum Dis.* 2000;59(1):5-11.
10. Dharti H., Dharti P., Himani D, Vidhi D. Prevalence of de Quervain's tenosynovitis and its effect on pinch strength in mobile users. *Int J Re Sci Research* 2018;9(3)
11. Samuel DJM, Braham SS, Vincent GGA, Joshua S, David JG. A review of De Quervain's stenosing tenosynovitis in the context of Smartphone use. *The J hand Surg* 2020; 25(2):133-136
12. Naseem A, Hafiz YI, Rabiya J, Tahniat W, Samra S. Occurrence of De Quervain's Tenosynovitis and its association with Short Message Service Texting Habit: A cross-sectional Study in the General Population of Karachi, Pakistan. *International Archives of BioMedical And Clinical Research* 2019; 5(1): 7-11.
13. Witt J, Pess G, Gelberman RH. Treatment of de Quervain tenosynovitis. A prospective study of the results of injection of steroids and immobilization in a splint. *J Bone Joint Surg Am.* 1991;73(2):219-222.
14. Zarin M, Ahmad I. Surgical treatment of De quervain's disease. *J Coll Physicians Surg Pak* 2003;13:157-8.
15. Scheller A, Schuh R, Honle W, Schuh A. Long-term results of surgical release of de Quervain's stenosing tenosynovitis. *In* 2009 Oct;33(5):1301-3
16. Gundes H, Tosum B. Longitudinal incision in surgical release of De Quervain disease. *Tech Hand Up Extrem Surg.* 2005;9(3):149-52
17. Ahmad I, Hussain K, Khan Z, Kashif S, Saeed M, Khan MA. Outcome of Surgical Release of 1st Dorsal Compartment of the Wrist for De Quervain's Tenosynovitis. *Med J Clin Trials Case Stud* 2021; 5(1): 000277
18. Lee HJ, Kim PT, Aminata IW, Hong HP, Yoon JP, Jeon IH. Surgical Release of the First Extensor Compartment for Refractory de Quervain's Tenosynovitis: Surgical Findings and Functional Evaluation Using DASH Scores. *Clin Orthop Surg.* 2014 Dec; 6(4): 405-09
19. Chang CY, Kheterpal AB, Vicentini JRT, Huang AJ. Variations of anatomy on MRI of the first extensor compartment of the wrist and association with De Quervain tenosynovitis. *Skeletal Radiol.* 2017 Aug;46(8):1047-1056.
20. Kumar K. Outcome of longitudinal versus transverse incision in De Quervain's disease and its implications in Indian population. *Musculoskelet Surg* 2016;100(1): 49-52
21. Ta KT, Eidelman D, Thomson JG. Patient satisfaction and outcomes of surgery for de Quervain's tenosynovitis. *J Hand Surg Am.* 1999;24(5):1071-1077.
22. Mellor SJ, Ferris BD. Complications of a simple procedure: de Quervain's disease revisited. *Int J Clin Pract.* 2000;54(2):76-77.
23. Rogozinski B, Lourie GM. Dissatisfaction after first dorsal compartment release for de Quervain tendinopathy. *J Hand Surg Am.* 2016;41(1):117-119.

CONTRIBUTORS

1. *Israr Ahmad - Supervision; Final Approval*
2. *Sabir Khan Khattak - Concept & Design*
3. *Noor Rehman - Data Analysis/Interpretation*
4. *Wasim Anwar - Critical Revision*
5. *Aamir Kamran - Drafting Manuscript*
6. *Azhar Hayat Khan - Concept & Design*
7. *Abdullah Durrani - Final Approval*



LICENSE: JGMDS publishes its articles under a Creative Commons Attribution Non-Commercial Share-Alike license (CC-BY-NC-SA 4.0).
 COPYRIGHTS: Authors retain the rights without any restrictions to freely download, print, share and disseminate the article for any lawful purpose.
 It includes scholarly networks such as Research Gate, Google Scholar, LinkedIn, Academia.edu, Twitter, and other academic or professional networking sites.